

# REVENUE DIVISIONAL OFFICER'S INQUIRY ON A NEWLY-WED WOMAN'S DISPUTED DEATH: TOE IMPRESSION INDICATED THE CAUSE OF DEATH – A REAL CRIME SCENE REPORT

**Nataraja Moorthy T, Nadiah Syariani M, Sivadurai SN, Saravanan K**

Corresponding author and Professor of Forensic Sciences, Faculty of Health and Life Sciences (FHLS), Management and Science University (MSU), Section 13, Shah Alam, Selangor, Malaysia. Formerly Government Forensic Crime Scene Investigator, Forensic Sciences Department, Government of Tamilnadu, India.

Forensic Lecturer, FHLS, Management and Science University, Section 13, Shah Alam, Malaysia.  
Sivadurai, Asst Director, Mobile Forensic Science Lab, Forensic Sciences Department, Government of Tamilnadu, India.

Supdt. of Police and Asst Director, NCB/ INTERPOL, Royal Malaysia Police, Federal Government of Malaysia

## Abstract

**Background:** Suicide is the way of ending one's own life. The method of suicide varies from country to country and common methods include hanging, poisoning, self-immolation and so on. In India the suicide rate of females is higher than males and many married women have been committing suicide for many reasons. The Indian legal system has taken steps to address this concern on married women by incorporating section of law which identify and punish the abettor. Under section 174(3) CrPC (Death of a woman within seven years of marriage), the Revenue Divisional Officer (RDO) should conduct an inquiry to determine the reason if any dowry harassment by husband and/or in-laws, behind the death of that married woman. During my forensic crime scene investigation career in India (1979-2003), RDO used to request Forensic Crime Scene Investigator (FCSI), Mobile Forensic Science Laboratory (MFSL), in such inquiries and to visit such death scenes and assist the investigation forensically and arrive the conclusion. One such indoor death scene, the author had visited and assisted the RDO, is presented herewith. **Gist of the case:** A woman aged 22 years old, married two years before found hanging in her house with feet touched the floor. The woman's father had lodged a complaint that her daughter was murdered by her husband and made her hang. The Inspector of Police arrived the scene and registered an FIR (First information report) under section 174(3) CrPC and informed the RDO. The RDO advised the Police Inspector to inform the forensic crime scene investigator to visit and assist the investigation forensically. **Crime Scene Observation:** The FCSI, also the corresponding author (TN) who immediately arrived the scene along with the Revenue officials made careful observations. On detailed examination of the scene and dead body, TN explained the RDO about the death scene and forensic findings. **Conclusion:** The author finally concluded that the death was due to suicidal hanging, based on the presence of toe impressions with other evidence.

**Keywords:** Crime Scene Investigation, Married Woman, Hanging, Alleged Homicide, RDO Inquiry

## INTRODUCTION

In the modern world, Forensic can be used not only to investigate crime scenes like homicide, burglary, sexual assault, fires and bomb blasts, but also non-crime doing civil wrongs such as willful pollution of air or water or causing industrial injuries [1]. Forensic is an important tool in any investigation and crime scene is the starting point of Forensic Science. All sciences can contribute to solve the crime and hence almost any sciences can be a forensic science [2]. Forensic investigation is based on the evidence found and located at the crime scenes since criminals always leave evidence either from the body in the form of impressions like finger impressions, foot/toe impression and from their belongings like tools to create tool impressions and so on [3]. Careful analysis of physical evidence can be used to establishing the guilt or innocence of somebody on court trials. Researchers have established that foot impressions are used to estimate stature [4], body weight [5] and gender [6]. Whenever dealing with dead bodies in crime scenes, the Field Criminalists or Forensic Scientists need to face challenges since the body position may cause confusion or complication to decide the cause of death. Hanging or self-suspension is a form of ligature strangulation where the pressure is produced by the weight of the body itself [7]. Suicide is the way of ending one's own life. The method of suicide varies from country to country and common methods include hanging, poisoning, firearms, self-immolation and so on. In India the suicide rate of females is comparatively higher than males and many married women have been committing suicide for many reasons.

The Indian legal system has taken steps to address this concern of married women by incorporating section of law which identify and punish the abettor. Under section 174(3) CrPC (Death of a woman within seven years of marriage), the Revenue Divisional Officer should conduct an inquiry to determine the reason like dowry harassment behind death of that married woman, once the Police Inspector registered the case. During my career in crime scene investigation, Revenue Divisional Officers (RDO) used to invite the author, former FCSI (TN) in such death scenes, to assist the investigation forensically and to arrive a conclusion. One such death case TN had visited in India and assisted the RDO, is presented herewith.

### GIST OF THE CASE

A woman aged 22 years old, married two years before found partially hanging in her house and the feet touched the floor as shown in figure 1. The woman's father who stayed near the house had lodged a complaint with Police stated that her daughter was murdered by her husband and made her hang as appeared in the crime scene.

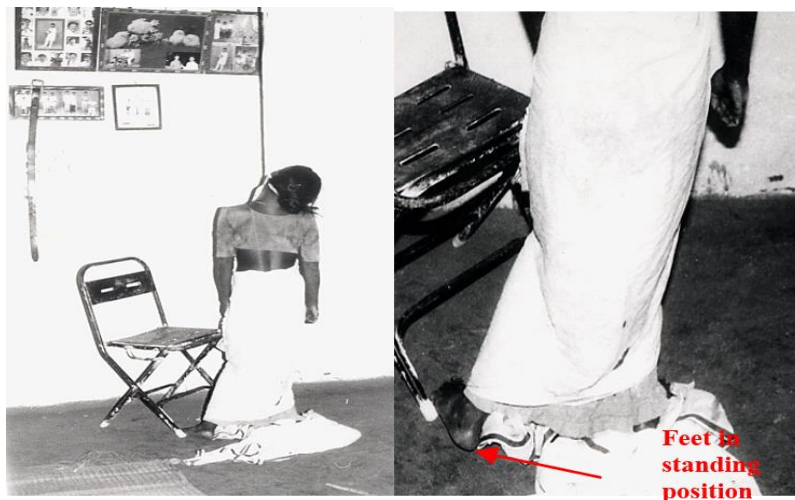


Figure 1: Hanging body with feet rest on the floor

The Inspector of Police arrived the scene and registered an FIR (First information report) under section 174(3) CrPC and informed the Jurisdiction RDO. The RDO immediately advised the Police Inspector to request the service of forensic crime scene investigator (FCSI), Mobile Forensic Science Laboratory (MFSL) and the Police Inspector requested the same.

### FORENSIC CRIME SCENE EXAMINATION

The former FCSI, the corresponding author immediately arrived the scene along with Revenue officials and made careful observation as shown in figure 2.

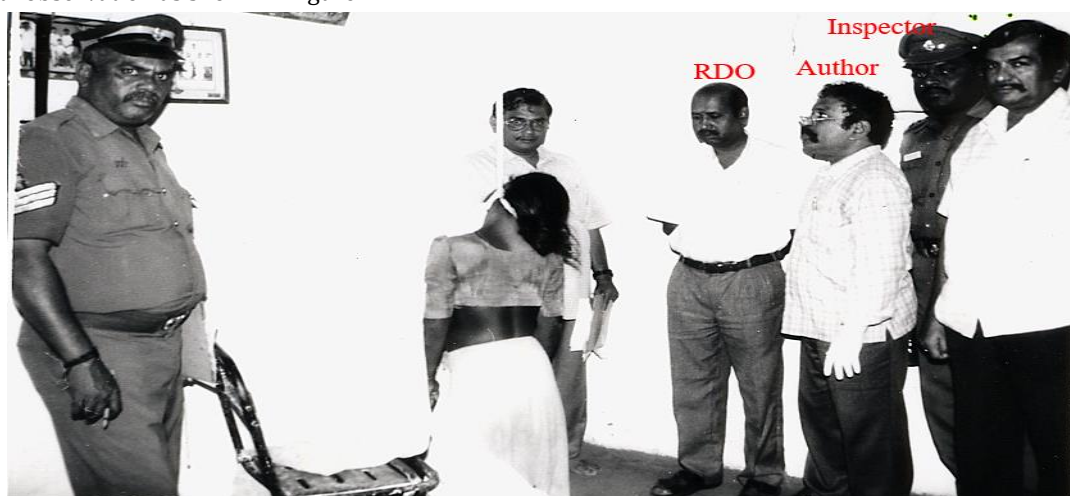
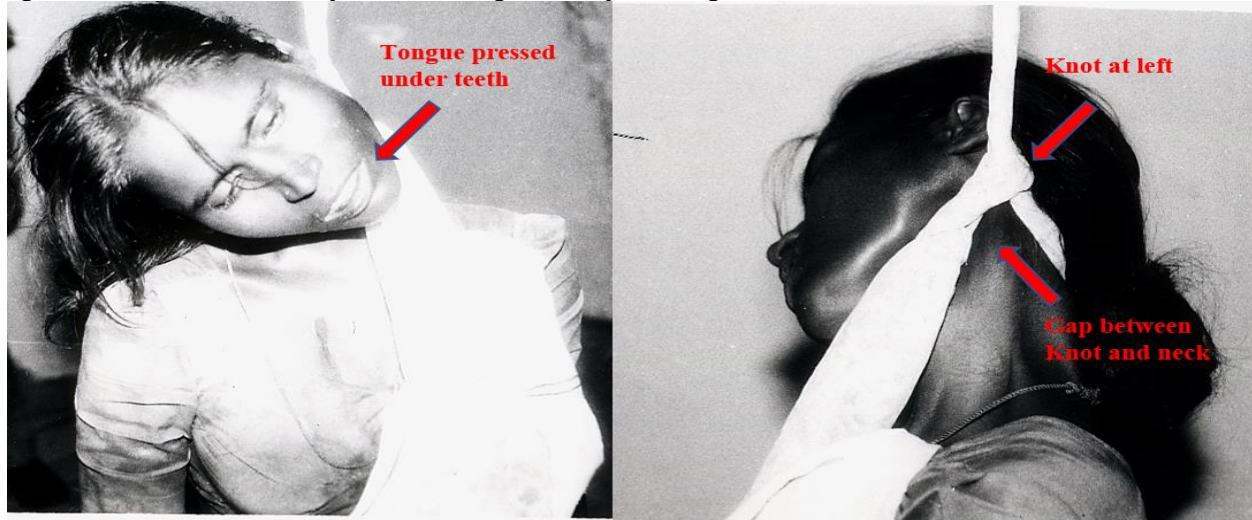


Figure 2: Author is examining the scene in the presence of Police and Revenue Officials

The body found hanging with incomplete suspension in a hall of the house with her face, facing the eastern

direction. Both legs of the deceased found touching the ground and the knees were in a semi flexed position (Fig1). The ligature material used was a twisted saree that tied into a noose went around the neck with a running knot of the neck while the other end of the ligature found tied at a rafter, under the roof. The eyes partly opened with tongue pressed under teeth. The knot was at the left side of neck, formed a gap between neck and ligature as shown in figure 3 wherein the noose encircled the neck by her weight. Hence a noncontinuous ligature mark found on the neck of the deceased, a characteristic feature in a suicidal hanging case. Since cloth was used to commit hanging, the ligature mark was broad and superficial and if nylon or coconut fibre ropes was used, the ligature mark would have deep and narrow against the present ligature mark.



**Figure 3: Tongue pressed under teeth and knot raised on the left side**

The author noticed a chair nearby, usually used by the individual before death to attach the ligature material to the high point such as beam, rafter, etc. Thus, the deceased should have brought the chair in this place of suicide with twisted saree and fixed one end of cloth in the rafter after step-up on the chair and formed the other end into a slip-knot which was placed around the neck as seen in the scene. When examined the folding chair, TN had surprisingly noticed right dust toe prints/impressions valuable forensic physical evidence very rarely available. The right dust toe impressions were collected by "lifting technique" and preserved for analysis. All the observations were documented with photography. Also, the author (TN) collected the toe impressions of the deceased in the crime scene itself by "inking method" for comparison and then the body was sent to Department of Forensic Medicine for autopsy. As a declared "Foot Print Expert", the author had compared the right dust toe impressions found on the metal folding chair with the dust impressions of the deceased in the crime scene itself. Based on comparison analysis, the author (TN) suggested that the dust toe impressions on the chair and toe impressions collected from the deceased are one and the same. Thus, the deceased used the metal folding chair to climb up and continued the process for her death. The author also presented his scene of crime report to RDO for use in his inquiry. The suicidal death was further confirmed by the autopsy report.

## DISCUSSION

Suicidal hanging is the form of violent death produced by suspending one's own body with a ligature around the neck. The present case report is a partial hanging rather than complete hanging since both feet of the deceased rest on the floor. The noose compresses the carotid arteries, which carry blood to the brain. The constriction force is because of her body weight<sup>[8]</sup>. The cause of suicide is found to be multi-factorial in which biological, psychological, social and environmental factors act together<sup>[9]</sup>. The ligature mark's direction may describe the position of knot and cause of death<sup>[10]</sup>. Ligature mark is the pressure mark on the neck underneath the ligature<sup>[11]</sup>. In the present case, the knot is seen at the left side. Mostly woman victims preferred their homes for committing hanging<sup>[9]</sup> as in the present in the indoor suicidal hanging. In hanging incidences like suicidal, homicidal or accidental, physical evidence such as dust, hairs, fibers, footprint, toe prints etc. may present and provide valuable information to the investigators and to arrive a conclusion. In this case report, toe impressions on the metal chair, a concrete physical evidence confirmed the act of suicidal hanging, rather than homicidal hanging, as alleged by the father of the deceased. As a forensic practitioner in India, the author himself had solved the mystery in some of the suspicious death and burglary cases, based on footprint evidence found at the crime scenes<sup>[12-14]</sup>. As an academican in Malaysia, the author has conducted research on toe prints<sup>[15-16]</sup> and toeless footprints<sup>[17]</sup> for selected populations and published the research findings in various journals. Forensic podiatrists have shown that footprint evidence in the crime scenes provide more information than fingerprints since footprints show individual characteristics<sup>[18-19]</sup>.

## CONCLUSION

The case report concluded with a fact that physical evidence present in challenging death scenes like partial hanging can indicate positive information lead to crime solvation. Hence the crime investigators must have the thorough knowledge on science and physical evidence so that any complicated or confused death scenes can be solved forensically. In this case report, the presence of toe prints put an end to the conflict statement of victim's father, as alleged homicide and impressed the confident on non-forensic personnel like Revenue Divisional Officers in the inquiry on dowry related deaths in India. Also the author (TN) explained the crime scene and the cause of death to the father of the deceased in the scene itself and finally the family members have accepted the scientific findings and fact.

## REFERENCES

- [1] Nataraja Moorthy T. (2020). Crime reconstruction, a tool to solve mystery and achieve justice – An interesting crime scene report. *Egypt J Forensic Sci Appl Toxicol.* 20(4):85-89.
- [2] Nataraja Moorthy T. (2019). Footprint evidence solved the mystery in a suspicious death: A rare case report. *Peer Review J Forensic & Genetic Sci.* 3(2):183-185.
- [3] Nataraja Moorthy T, Santhra Segaran B, Srinivasan M. (2020). Suspicious death – Trace evidence identified the complainant as accused: A real crime scene report. *Int J Medi Tox Leg Med.* 23(1-2): 117-119.
- [4] Nataraja Moorthy T, Ang YL, Saufee AS, Nik F. (2014) Estimation of stature from footprint and foot outline measurements in Malaysian Chinese. *Austral J Forensic Sci.* 46 (2):136-159.
- [5] Nataraja Moorthy T, Hairunnisa M. (2018). Body weight estimation from footprint anthropometry in Lun Bawang ethnic of east Malaysia. *Medico-Legal Update.*18(2): 164-169.
- [6] Nataraja Moorthy T, Murty OP. (2019). Suspicious death – Crime scene evidence indicated the cause of death: An interesting multiple death case report. *Int J Medi Tox Leg Med.* 22(1-2): 5-7.
- [7] Ali E et al. (2014) Suicide by hanging: a case study of 334 cases. *Bangla Med J.* 43(2): 90-93
- [8] Anny Sauvageau. (2011). About strangulation and hanging: Language matters. *J Emerg Trauma Shock.* 4(2): 320.
- [9] Pal SK, Rana A, Sharma A, Kaushik N and Sehgal A. (2018) A Forensic Analysis of Ligature Material in Suicidal Hangings. *Int J forensic Sciences.* 3(2):1-14.
- [10] Santo Gratteri and et al. (2017). When a suicide becomes a forensic enigma: The role of hanging marks and tools of suspension. *Medi Leg J.* 85(3):141-144.
- [11] Arif M. (2015). Ligature mark on the neck; How elucidative? *Professional Med J.* 22 (6):798-803.
- [12] Nataraja Moorthy T. (2007). Forensics of Suspicious Death. *Tamilnadu Police J.* 1 (3):78-99.
- [13] Nataraja Moorthy T. (2008). Gait pattern analysis in crime scene investigation. *Tamilnadu Police J.* 2 (3):61-70.
- [14] Nataraja Moorthy T. (2000-2001). Keen crime scene observation – Hoof marks fixed the accused. *Forensic Sci & Tech News Digest.* 2 (4):6. (A Central Bureau of Investigation Publication).
- [15] Nataraja Moorthy T, Hairunnisa M. (2010). Gender variation from toe print ridge density among Melanau ethnic in Malaysia Borneo Island. *Int J Med Tox Leg Med.* 22 (1-2):8-12.
- [16] Nataraja Moorthy T, Devina KD, Ivan Nikkimor LD, Ariel Philip IP. (2021). Gender determination from toe prints among Kagay Anons of Philippines for forensic applications. *Indian J Forensic Med Tox.* 15 (2):1125-1130.
- [17] Nataraja Moorthy T, Hairunnisa M. (2018). Sex determination from toeless footprint among Ibans, an indigenous ethnic group in Malaysian Borneo. *Forensic Sci. Add Res.* 3 (15):1-5.
- [18] Nataraja Moorthy T, Siti Fatimah S. (2015). Individualizing characteristics of footprints in Malaysian Malays for person identification in forensic perspective. *Egypt J Forensic Sci.* 5:13-22.
- [19] Nataraja Moorthy T, The Yoong Mond. (2018). Individualizing characteristics of footprints in Malaysian Chinese for person identification in forensic perspective. *J South Ind Med Leg Assoc.* 10(2): 59-69.